

Laminitis in Dairy Cattle

Like most dairy producers, you've probably seen evidence of laminitis in at least some of your cows at one time or another. Perhaps you've noticed that some of your fresh animals suddenly become lame shortly after calving. Or maybe a few of your older cows have hooves with horizontal grooves and long, curling toes. In such cases it's likely that those animals are suffering from laminitis.

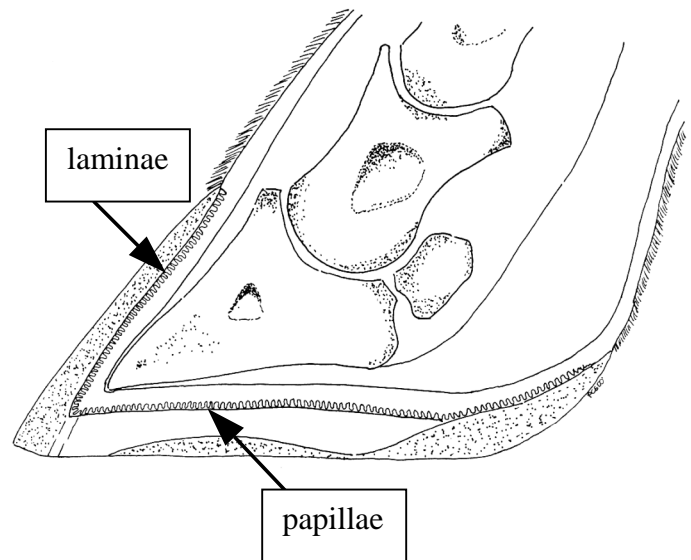
Why should you care?

Laminitis is painful for your cows, and each case drains money from your pocket. There is the cost of treating any diagnosed cows and culling cows that otherwise would have remained part of the herd. A cow with laminitis is also reluctant to stand, resulting in lower feed consumption and lower milk yields, with losses of up to 2.8kg of milk per cow per day¹. It is also more difficult to detect heats in animals suffering from laminitis because they will be unwilling to stand to be mounted, leading to a lowered reproductive efficiency.

¹Rajala-Schultz et al., J. Dairy Sci. 82:288 (1999)

What is laminitis?

Laminitis is an inflammation of the laminae and papillae in the hoof. The layer of tissue inside the hoof, closest to the hoof wall is arranged in regular folds. It is this folded tissue that we are referring to when we talk about the laminae. The equivalent layer of tissue in the sole of the hoof is arranged in irregular folds called the papillae. Both the laminae and the papillae act to absorb the shock created by the hoof's impact with the ground. They also produce the horny tissue of the wall and sole. Anytime the blood supply to these tissues is disrupted - through damage to the vessels from internal or external elements - laminitis



The inside of a cow's hoof.

can result.

There are three phases of laminitis: acute, sub-clinical and chronic laminitis. Acute laminitis is commonly associated with feeding diets too high in concentrates. Sudden changes in diet to higher concentrate rations can cause a condition called acidosis in the rumen. Acidosis causes the release of chemicals into the blood stream, which then travel to the vessels of the hoof. These chemicals can gradually destroy the vessels supplying the hoof tissues with blood. Without an ample supply of blood the laminae and papillae begin to die. The dead tissues swell, causing tremendous pressure within the rigid hoof wall. The pressure also compresses the living blood vessels - further reducing blood flow - and causing intense pain.

Sub-clinical laminitis is the most common form of laminitis found in modern dairy operations. This phase of the disease can result from physical injury to the hoof or from damage sustained during acute laminitis. Either way, the layers of tissue between the pedal bone and the hoof wall begin to degenerate, meaning that the pedal bone begins to separate from the hoof wall

and sole. At the same time, the damaged tissues are unable to produce horn of the same quality as healthy tissues, leading to a softening of the outer wall and sole of the hoof. Softening of the outer hoof makes it more prone to wear and damage, compounding the problem. If the disease remains untreated it will progress to chronic laminitis.

During the chronic phase of laminitis, the mechanical damage occurring within the hoof becomes permanent. As the laminae and papillae continue to deteriorate, the pedal bone becomes completely separated from the hoof wall, and possibly the sole. Having lost its attachments to the inside of the hoof, the pedal bone rotates so that the front tip points downward, towards the sole. In severe cases, the tip of the pedal bone may actually come through the sole or the entire pedal bone may sink down to the level of the sole.

How can you tell if your cows have laminitis?

The answer to this question depends on the stage of laminitis each cow has developed. A cow that has acute laminitis will likely appear clinically lame, with her feet pulled underneath her body and her back arched. She will often exhibit redness and swelling in the tissues just above the hoof wall and she will be unwilling to stand or walk.

If you've never noticed a cow with sub-clinical laminitis in your herd, you may be excused. It is only with hoof trimming that signs of sub-clinical laminitis such as yellowish discoloration of the sole, sole hemorrhages, sole ulcers, double soles, and separation of the white line can be seen. This makes regular hoof-trimming important for three reasons. Firstly, trimming allows you to keep track of how many cows in your herd have developed sub-clinical laminitis. Secondly, trimming will help cows with sub-clinical laminitis to recover (as long as

the hoof is not continuing to be damaged). Thirdly, proper trimming is a good way to help prevent healthy cows from developing sub-clinical laminitis.

Cows with chronic laminitis may be the easiest to spot. Destruction of the horn-producing tissues disrupts the growth pattern, changing the shape of the hoof. A cow with chronic laminitis will have elongated, flattened, broadened hooves with grooves and ridges on the hoof wall, giving it a rippled appearance. She will also be walking on her heels rather than on her toes and the tips of her toes will curl upwards. This is because the heel continues to grow at a more normal rate while the growth of the front wall is slowed. If her hooves are trimmed sole ulcers, sole hemorrhages, double soles, and yellowish discoloration may be seen.

Risk factors for laminitis

Many producers are aware of the link between concentrate feeding and laminitis, but other important risk factors shouldn't be overlooked. A study on sub-clinical laminitis by a Swedish researcher² found that first-calf cows were more likely to show signs of sub-clinical laminitis than older cows. In fact, as a cow aged her chances of developing sub-clinical laminitis decreased.

Other studies have found that environmental factors can also increase the risk of sub-clinical laminitis. Steps or curbs greater than 15cm in height have been linked to laminitis³. This may be because cows are forced to transfer their weight onto the hind feet either for a long period of time (if the curb is in front of the feeder) or repeatedly during the day (if the curb is at the entrance to the parlour or the stalls). Inadequate bedding in the stalls can also lead to laminitis problems, possibly due to longer standing times and greater half-in, half-out standing⁴. Hard floors, such as concrete, may aggravate problems caused by

increased standing times and can predispose cows to developing laminitis⁵.

The development of laminitis in cows is not fully understood. Therefore, there is a need for further research into the causes and effective preventative measures for laminitis. Researchers at the University of BC are currently investigating how to improve cows' environmental conditions to prevent sub-clinical laminitis.

²C. Bergsten, Acta Vet. Scand. 35:55 (1994)

³J.M. Philipot et al., Vet. Res. 25:244 (1994)

⁴P. Colam-Ainsworth et al., Vet. Rec. 125:573 (1989)

⁵C. Bergsten and B. Frank, Acta Vet. Scand. 37:383 (1996)

Which animals are most at risk?

Nutrition related problems:

- **Those fed the highest grain levels**
 - **rumen acidosis**
 - **large population of gram-negative bacteria releasing endotoxins**
- **Animals close to calving**
 - **risk factors related to pregnancy**
- **Fresh cows (2-4 months into lactation)**
 - **change in diet and environment**

Environment related problems:

- **Animals exposed to uncomfortable environments**
 - **concrete floors**
 - **high curbs**
 - **uncomfortable stalls**

Health related problems:

- **Animals suffering from other diseases**
 - **especially diseases of the udder**

By: Erin Bell, University of BC